

# Too little, too late: Athletic hip injury

Mr David Filan and Mr Patrick Carton discuss the pathogenesis, screening and management of athletic hip injury and how to improve outcomes in this patient population

## Case report 1

A 34-year-old, former inter-county Gaelic footballer (six years), was referred to the clinic with a history of persistent, severe pain in the right hip, which has come to affect his daily quality of life (sleeping, driving, any long journeys) for the last six months. At time of initial consultation, he was no longer able to play sports or run due to pain. He suffered from chronic, recurrent groin discomfort during his inter-county career. On examination, there was marked global stiffness and he had lost a significant amount of flexion, all rotation and adduction of the flexed hip. X-rays confirmed significant osteoarthritis. Due to increasing discomfort, limping and inability to perform daily activities, he decided to proceed with total hip replacement 11 months later.

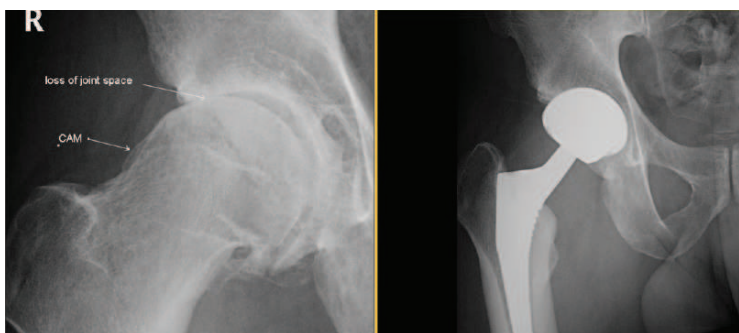

Figure 1(a): Osteoarthritis. Severe supra-lateral articular cartilage degeneration as a result of untreated chronic FAI

Figure 1(b): Arthroplasty. Uncemented ceramic-on-ceramic total hip replacement. Arthroscopic surgery not suitable for OA

## Case report 2

A 28-year-old male competitive rugby player (playing since he was eight years old) presented with a gradual onset of symptoms for over four years. Imaging of his hip was undertaken three years earlier at another institution, revealing osseous prominences suggestive of early CAM-type morphology.

At time of presentation to our clinic, he complained of a moderate level of pain, slight limp and difficulty putting on shoes/socks. X-rays taken demonstrated that his left hip had signs of established osteoarthritis (OA) and would not benefit from preservation surgery. Magnetic resonance arthrogram (MRA) demonstrated joint space narrowing and thinning of the articular cartilage and the presence of a paralabral cystic degeneration.

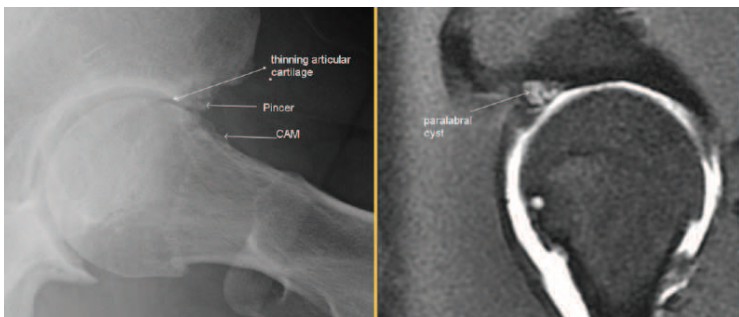


Figure 2(a): False profile view: Osteoarthritis. Severe anterior articular cartilage degeneration as a result of untreated CAM and pincer FAI

Figure 2(b): MRA. Superior joint-thinning, paralabral cyst and CAM cyst in keeping with chronicity of FAI

During the last decade in particular, the movement-associated clinical disorder known as femoroacetabular impingement (FAI) has become commonly recognised as the source of chronic hip and groin pain. The prevalence is estimated to be 10-to-15 per cent of the general population and is significantly higher among athletes (as much as 72 per cent reported for field-based athletes). As knowledge about this mechanical problem has advanced, its contribution to the premature degeneration of the hip is becoming clearer. FAI occurs when there is abnormal, repetitive contact between the ball-and-socket structures of the hip joint as it moves. This can begin to occur from as young as 10-to-12 years of age when the naturally spherical femoral head becomes misshapen (known as a CAM deformity) or when the acetabular rim of the socket develops excess bone (known as a Pincer deformity). For the most part, these abnormalities are developmental in nature and become progressively worse over time. A CAM can result in a shearing force on the labrum (whose function is to provide depth and stability to the hip socket), as well as

to the protective covering of the hip surface (articular cartilage). A pincer will also cause destruction to the labrum and articular cartilage. The risk of developing osteoarthritis (OA) as a result of damage to these protective structures then becomes inevitable.

## Pathogenesis

The general consensus is that higher demands placed across the hip joint contribute to FAI-associated deformities becoming symptomatic, consequently leading to accelerated cartilage wear. When considering the requirements being expected from the joint in terms of activity regimes, as a clinician, it is important to know when to act and what management route to take to preserve optimum functioning of the hip joint. In all cases, particularly for the developing athlete, early diagnosis is vital to prevent irreversible damage to the articular cartilage.

## Management

Given the limitations of access to x-ray and magnetic resonance arthrogram (MRA) scanning, the physiotherapist or GP attending a symptomatic athlete must have a high index of suspicion to the possibility of an underlying hip pathology. Careful evaluation of potential symptoms coupled with a thorough clinical examination will alert the practitioner to early signs of FAI.

Unfortunately, as we see in our clinic all too often, athletes are referred too late, considering the duration of their symptoms. In the two case studies in this article, all athletes reported a long-standing, identifiable hip/groin issue, which they have struggled to alleviate with conservative management. It is worth mentioning that a period of conservative management towards alleviating acquired hip and groin symptoms should always be trialled initially. However, the question then arises of how long an athlete should persevere with conservative treatment for FAI when a mechanical bony restriction is hindering any observable results.

## Evidence-based results

There are very few studies evaluating outcomes, such as return to sport or duration of any lasting benefits from conservative treatment alone. More focused comparative trials are needed to substantiate this as a viable treatment option for FAI.

In order to determine the impact of a particular treatment course for symptomatic FAI, it is necessary to objectively evaluate outcome. There is an overwhelming international body of evidence that demonstrates the successful results of arthroscopic surgery in the treatment of athletes with symptoms from hip impingement. For the past decade at The Hip and Groin Clinic, outcome measures have been an important component of clinical practice for all patients undergoing surgical treatment for symptomatic FAI.

The premise behind arthroscopic preservation surgery is to prevent the further degradation of the hip and subsequent development of OA by correcting abnormal and destruc-

tive hip mechanics and repairing protective structures such as the labrum and stabilising the hip capsule. A specialised technique (labral cuff repair) developed and only performed at UPMC Whitfield has this focus in mind; relieving pain in 97.1 per cent of cases and enabling a return to sports in 94.2 per cent of cases.

Ultimately, the aim is to avoid the need for premature hip replacement, while restoring quality of life and athletic performance. An important point to note is that the potential for lasting benefits of surgery are largely related to the initial integrity of the hip joint, as well as surgeon experience. The emphasis is therefore directed toward the hip in its pre-arthritis state, ideally before the onset of irreversible cartilage damage.

One of the most identifiable radiographic signs and a relative contraindication for preservation surgery is a significant loss of joint space (generally evidenced by Tonnis Grade >2 or <2mm of joint space). The arrival to this state is progressive and in retrospect all symptomatic athletes will reveal that throughout their sporting career they continued to play with symptoms and ignored warning signs such as stiffness after activity, recurrent groin pain, recurrent hamstring tightness and reduced range of hip movements.

In cases where athletes are presenting with these recognised symptoms, appropriate onward referral should not be delayed.

## Screening for FAI

Naturally, there will always be an increased prevalence of OA with increasing age, among athletes in particular but also within the general population as a whole. In a recent screening study undertaken at the Hip and Groin Clinic, a cohort of asymptomatic GAA athletes were assessed for prevalence of signs and symptoms known to be associated with FAI. In this study of 124 athletes, 59.3 per cent reported stiffness in one or both hips; 43.1 per cent experienced pain in the hip/groin; impingement testing (pain on hip flexion, internal rotation and adduction, FADIR) was positive in 27 per cent of hips; flexion was reduced in 10.1 per cent of hips (<114°); and internal rotation was reduced in 23.8 per cent of hips (<27°). The results of this study revealed a high proportion of athletes demonstrated symptoms and signs in keeping with underlying FAI. Further longitudinal screening studies are needed in order to be able to understand the relationship between early warning signs and the progression to symptomatic FAI or OA, with the hope of putting preventative strategies in place before irreversible damage is done.

Outcomes from our clinic show that those who have symptoms for more than two years prior to scheduling surgical intervention, while improving significantly from their pre-operative state, have poorer outcomes compared to those who have initial symptoms for less than two years. Arthroscopic surgery generally yields superior outcomes for those at the younger age spectrum. For the 2,000+ athletic cases undergoing

surgical management, one-in-three cases reported symptom duration longer than two years and all had exhausted conservative treatment, with prior attendance to an average of 2.7 HCPs for their symptoms.

## Quality-of-life (QoL) and economic toll of FAI

While improved quality of life and symptomatic relief are the objective for any clinician dealing with a case of hip and/or groin issues, the effect of a particular treatment regimen toward achieving these goals must also be scrutinised. One recent study compared the cost-effectiveness of hip arthroscopic surgery against structured rehabilitation alone for the treatment of labral tears in patients without OA. It was found that hip arthroscopy was more cost-effective and the lifetime incidence of symptomatic OA was over twice as high for patients treated with rehabilitation compared to arthroscopic surgery. Timely recognition and diagnosis of related conditions, such as labral tears, are an important source of cost-effectiveness.

It is important that not only the patient, but also GPs and other healthcare practitioners who are collaboratively involved in the treatment of an athlete with hip and groin symptoms are provided with up-to-date outcomes, both surgical and conservative.

## Summary

- Athletes are particularly prone to developing symptomatic FAI due to the twisting/turning, acceleration/deceleration aspects of their sports.
- Evidence-based research suggests that FAI causes OA.
- Red-flag warning signs of possible FAI:
  - Stiffness post-activity.
  - Recurrent groin pain.
  - Reduced flexibility.
  - Recurrent hamstring tightness.
- Accurate diagnosis requires radiographic-specific imagery, in addition to patient history and clinical examination.
- Delay in diagnosis (symptoms >two years) can lead to poorer long-term outcomes.
- Preservation surgery can produce excellent outcomes, provided early diagnosis is made.
- The most appropriate course of treatment can only be given once all possibilities are explored. Clinical outcomes and structured follow-up are vital to assess the outcome of intervention.

Mr David Filan, Clinical Research Assistant, The Hip and Groin Clinic, UPMC Whitfield, Waterford, and Mr Patrick Carton, Consultant Orthopaedic Surgeon (specialist in hip and groin surgery), UPMC Whitfield, Waterford. For further information, please contact pcartonsecretary@hipandgroinclinic.ie, or visit the websites [www.sportship.com](http://www.sportship.com) or [www.hipandgroinclinic.ie](http://www.hipandgroinclinic.ie).